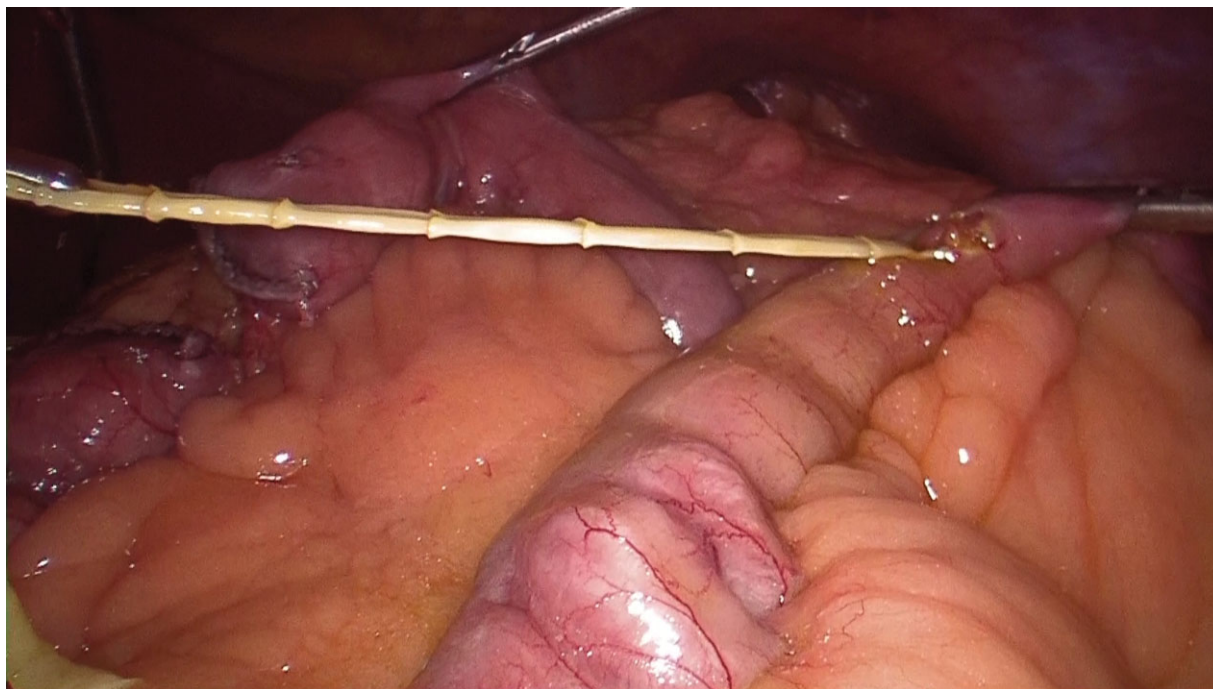


Taenia saginata: unexpected finding during laparoscopic Roux-en-Y gastric bypass

While performing the jejunum-jejunal anastomosis during a laparoscopic Roux-en-Y gastric bypass to treat morbid obesity, a yellowish filamentous structure appeared from the bowel lumen. It was removed, and subsequent microbiological analysis reported it to be a *Taenia saginata* (a tapeworm).



Ester Ferrer-Inaebnit^{1,*}, Alejandro Metzger², Markus Naef² and Yannick Fringeli²

¹Department of General Surgery, Hospital Universitario Son Espases, Palma de Mallorca, Spain

²Department of Visceral Surgery, Hirslanden Clinic Beau-Site, Bern, Switzerland

*Correspondence to: Ester Ferrer-Inaebnit, Hospital Universitario Son Espases, Cirugía General y Digestiva, Carretera de Valldemosa 78, 07010 Palma de Mallorca, Spain (e-mail: esterinaebnit@gmail.com)